

One Patient, One Database, One Report

9/21/2011

Rimed Hospital
Neurology Department
Dr. Hamilton



TCD Examination: Intracranial Unilateral

Patient Details

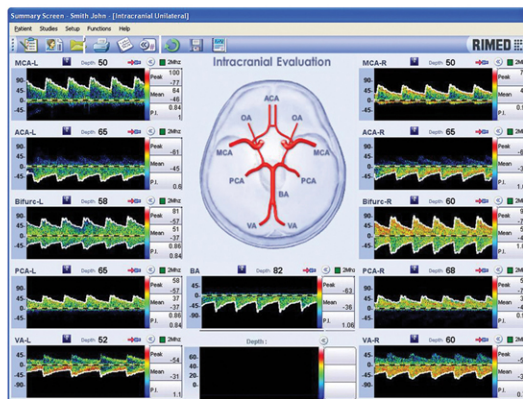
Examination Date and Time: 9/20/2011 05:17
 ID: 123456 Last Name: Smith Middle Name: First Name: John
 Sex: Male Age: 71
 Home Phone: E-Mail:
 Cellular Phone: Address:
 Work Phone:
 Referred By:
 Reason For Examination:

Patient History

Smoking: No CVA: No Symptomatic Carotid Stenosis: No
 Hypertens: No Atrial Fibrillation: No Asymptomatic Carotid Stenosis: No
 TIA: No Coronary By Pass: No Prosthetic Heart Valves: No
 Arrhythmia: No

Examination History

Date	Time	Type
9/20/2011	05:17	Intracranial Unilateral



Left Side							Right Side							
	Depth (mm)	Peak cm/sec	Mean cm/sec	P.I. ratio	HITS cm/sec	DV cm/sec		Depth (mm)	Peak cm/sec	Mean cm/sec	P.I. ratio	HITS cm/sec	DV cm/sec	
MCA	50	100 -77	64 -46	0.84 1		46 -31		50	71	43	0.98		29	MCA
ACA	65	-61	-45	0.6		-34		65	-63	-38	1.03		-24	ACA
Bifurc	58	81 -57	51 -37	0.86 0.84		37 -26		60	91 -77	53 -46	1.09 1		33 -31	Bifurc
PCA	65	58 -57	37 -37	0.86 0.84		26 -26		68	57 -77	35 -46	0.94 1		24 -31	PCA
VA	52	-54	-31	1.1	7	-20		60	-59	-39	0.79		-28	VA

Middle						
	Depth (mm)	Peak cm/sec	Mean cm/sec	P.I. ratio	HITS cm/sec	DV cm/sec
BA	82	-63	-36	1.06		-25

Manage Digilite™ IP images

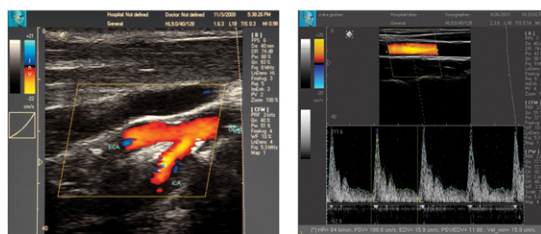
Indication

9/20/2011 6:50:35 AM - TIA

Interpretation

9/20/2011 6:51:22 AM - No pathological findings.

Signature:



Digilite™